



PATIENT

T.J. Muscato

PRESENTING CLINICAL SIGNS

History: History asthma x one year. Grade III/VI murmur. Increased coughing. Mild crackles left side on PE. Bronchial thickening on radiographs, c/w bronchial asthma. BP: 140mmHg.

SPECIES

Feline

ECHOCARDIOGRAM FINDINGS

2D, m-mode, color flow and Doppler imaging is available.

BREED

Bengal

Left ventricle: The LV diameter is normal with adequate myocardial function. The LV wall is highly asymmetric with severe septal thickening contrasting regions of thinning and mild to moderate free wall hypertrophy. There is a diffusely hyperechoic endocardium consistent with fibrosis. The papillary muscles are mildly hypertrophied and hyperechoic with regions of remodeling.

SEX

Male Neutered

Left atrium: The left atrium is mildly dilated. No smoke or thrombi seen.

Mitral valve: The anterior leaflet of the mitral valve appears normal. Mild eccentric MR.

Aortic valve/Aorta: The aortic valve is normal in morphology and mobility. Mildly elevated aortic outflow velocity with a dynamic profile, likely secondary to the LVOT bulge. No aortic insufficiency.

AGE

9 years

Right ventricle: Normal right ventricular diameter and morphology indicating no overt evidence of pulmonary arterial hypertension.

Right atrium: The right atrium is normal in dimension.

Tricuspid valve: The tricuspid valve appears normal with no tricuspid regurgitation.

WEIGHT

18lbs

Pulmonary valve/Pulmonary artery: The pulmonic valve is normal in morphology and mobility. No pulmonic insufficiency. Normal RVOT velocity; laminar flow.

Pericardium/other: No pericardial or pleural effusion noted. No obvious cardiac masses.

Heart rhythm: ECG reveals a sinus rhythm with an average HR of 160bpm. Inverted QRS.

INTERPRETED BY

Maggie Machen
Lamy, DVM
DACVIM (Cardiology)

2-Dimensional Measurements

Ao diam (cm)	1.2
LA diam (cm)	1.6
LA:Ao (Swe)	1.4
IVS thickness (cm)	0.93
LVID diastole (cm)	1.5
PW thickness (cm)	0.73
LVID systole (cm)	0.45
FS (%)	70

Doppler Measurements

PV Vmax (m/s)	0.74
AoV Vmax (m/s)	2.2
MR Vmax (m/s)	NA
TR Vmax (m/s)	NA
TR PG (mmHg)	NA

IMAGING

PERFORMED BY

Pamela Harrigan,
RDMS

HOSPITAL NAME

Halifax Veterinary
Hospital

INTERPRETATION OF THE FINDINGS

The diagnosis and cause of the murmur is hypertrophic obstructive cardiomyopathy. This indicates some degree of LV thickening (significant and irregular in this case), with a dynamic obstruction. The obstruction appears to be solely due to the septal bulge and is mild in nature. There is mild left atrial dilation, indicating the risk for progression to spontaneous CHF and/or a thrombotic event is currently low. No additional issues are identified. In this normotensive cat, hyperthyroid disease should be ruled out as a contributing factor.

REFERRING VET

Dr. Hopkins

INVOICE

27074

While no medications have been shown to definitively alter long term outcome at this stage of disease, atenolol is often initiated to decrease the outflow obstruction. If there is difficulty medicating at home or this is contraindicated with severe underlying respiratory disease, an alternative approach would be closely monitoring for progression in the next 6 months. This is likely a reasonable approach, given only a mild obstruction.

DATE

10/24/22



PATIENT T.J. Muscato
 Prognosis is guarded long term, given the highly variable rates of progression in subclinical feline cardiomyopathy.

SPECIES Feline
 Even with disease identified here, this is unrelated to respiratory signs and crackles, these are considered likely to be primary respiratory in origin.

RECOMMENDATIONS

- If elected/able, administer titrating dose of atenolol: 25mg tablets; Give ¼ tab once daily. Recheck heart rate in 1-2 weeks with target stressed rate of 140-160bpm 12-24 hours post-administration. Increase as needed until target reached.
- Screening T4 if not recently performed. Monitor BP/T4 q6 months lifelong.
- Anesthetic risk is considered moderately elevated and judicious IV fluid rates are advised to avoid fluid overload. Additionally, drugs that stimulate heart rate should be avoided unless clinically necessary (glycopyrrolate, atropine). Avoid vasodilators as this may worsen the obstruction. A reasonable protocol includes opioid/benzodiazepine premedication, propofol induction, isoflurane maintenance.
- Monitor for any clinical evidence of cardiac compromise, including respiratory changes and/or signs of a blood clot event (paralysis, neurologic changes, etc.).

PLAN

- Recommend recheck echocardiogram in 6 months to assess rate of progression, sooner if any issues arise in the interim.

BREED Bengal

SEX Male Neutered

AGE 9 years

WEIGHT 18lbs

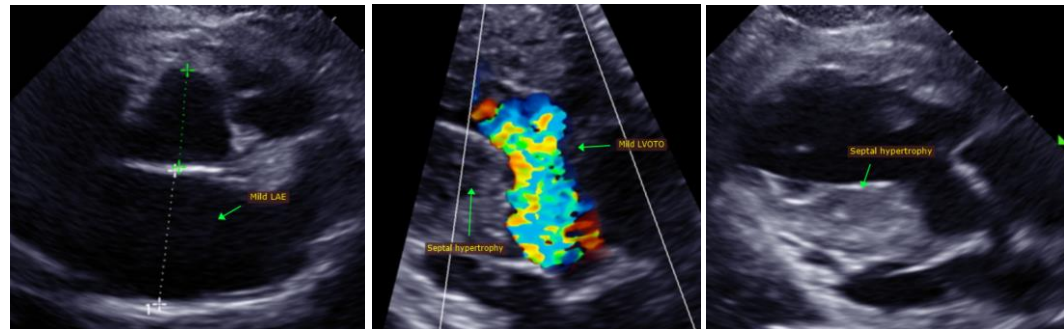
INTERPRETED BY

Maggie Machen Lamy, DVM
 DACVIM (Cardiology)

IMAGING PERFORMED BY

Pamela Harrigan, RDCS

IMAGES



HOSPITAL NAME

Halifax Veterinary Hospital

The information and recommendations provided are based on the images presented by the referring veterinarian. No evaluation can be communicated regarding pathology that was not visible in the image/video clips provided.

REFERRING VET

Dr. Hopkins

Thank you for this referral. This report was generated using transcription software, and minor dictation errors may be present. If the clinical or image interpretation does not parallel your findings or if I can be of any further assistance, please contact me.

INVOICE

27074

Maggie Machen Lamy, DVM
 Diplomat of the American College of Veterinary Internal Medicine (Cardiology)
 info@sonopath.com

DATE

10/24/22